

Primary Stabbing Headache

Name: Dr Hooi Ling Teoh, MBBS

Institution: Sydney Children's Hospital

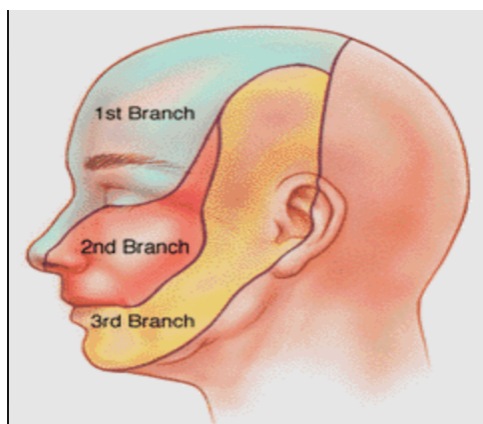
Date: 28/06/2013

Primary stabbing headache, also known as “ice-prick” headache is a relatively common headache syndrome. They occur spontaneously and are not associated with other organic disease. This headache is characterized by intense stab of sharp, jabbing pain that occurs in a small, localized area of scalp, usually in the distribution of the 1st division of the trigeminal branch (see picture 1). It frequently occurs on one side. These stabs can be single or occur in a cluster and are alarming and will stop patients in their tracks. They can last from a fraction of a second to 10s and can occur at irregular intervals with variation from one occurrence to many times a day. This headache in adults can be associated with other type of headaches such as migraine, tension-type headache and cluster headache. A patient may experience accompanied vision loss and “red eyes” (conjunctival haemorrhage).

The prevalence is 35.2% with a female preponderance and a mean age of onset at 28years (1). Primary stabbing headache has been described in both adults and children. In children, the age of onset is 7years old and is usually not associated with other primary headaches (2).

The differential diagnosis of primary stabbing headache includes SUNCT syndrome (short lasting unilateral neuralgiform headache), occipital or other cephalic neuralgias, trigeminal neuralgia, nummular headache, and traumatic scalp injury.

Treatment is rarely necessary due to the attacks being benign and mild. In patients with more severe symptoms, therapy may be indicated. Drug therapy that has shown to work for this condition is indomethacin (3), gabapentin, melatonin (5), and COX2. In children, this condition has a good prognosis with 70% of patients being asymptomatic after 1-5years (2).



1. *Trigeminal nerve distribution.*

Reference:

Reference:

- 1) Sjaastad O et al. The Vaga study: epidemiology of headache I: The prevalence of ultrashort paroxysms. *Cephalgia* 2001;21: 207
- 2) Soriani S et al. Juvenile Idiopathic Stabbing Headache. *Headache* 1996; 36: 565-567
- 3) Fuh JL et al. Primary stabbing headache in a headache clinic. *Cephalgia* 2007; 27:1005
- 4) Franca et al. Gabapentin-responsive idiopathic stabbing headache. *Cephalalgia* 2004;24: 993-996
- 5) Rosen TD. Melatonin as treatment for idiopathic stabbing headache. *Neurology* 2003; 61:865