

Progress Report
Brain Foundation

Author: Professor Stephen Bowden

Qualification: PhD

Institution: University of Melbourne

Date: October 2016

Title of Project

Automating brain scan analysis to improve the diagnosis of Alzheimer's disease in clinical practice

Summary

Diagnosis of Alzheimer's disease (AD) is a complex process and may take approximately three years from onset of symptoms to receive a firm diagnosis of dementia. The number of people living with dementia is expected to continue to rise, therefore, early and timely detection of AD or mild cognitive impairment (MCI) is a high priority, as this allows symptomatic intervention and planning of care prior to further neurodegeneration. Furthermore, when available, pharmaceutical agents are most effective during the early clinical stages of the disease.

Currently, structural MRI is routinely performed to exclude complicating conditions that may cause cognitive symptoms, such as hydrocephalus, tumours or vascular disease, but not for confirming presence of AD or MCI. However, there has been burgeoning interests in the incorporation of neuroimaging biomarkers into routine assessment to enhance neurodegenerative disease. Furthermore, volumetric, structural MRI is shown to follow most closely to clinical phases of AD disease progression. Atrophy in both the hippocampus and entorhinal cortex are recognised to be reliable markers of AD. Reduced hippocampal volume is recognised as a sensitive biomarker to AD and people with MCI have lowered entorhinal cortex volumes even prior to the diagnosis of MCI. However, degenerative pathology of AD is thought to begin in the perirhinal cortex before spreading to the entorhinal cortex and

hippocampus, hence specific measurements of perirhinal cortex may prove to be a sensitive biomarker of preclinical AD. Volumes of both entorhinal and perirhinal cortex are significantly smaller in MCI. Reduced entorhinal and perirhinal volumes have also been shown to be a good predictor of future cognitive decline.

There is therefore good evidence of the potential advantages of incorporating hippocampal, entorhinal and perirhinal volumetric measurements into a diagnostic model. While manual delineation of brain structures remains the gold standard, the past decade has seen constant evolution of automated tools to measure MRI brain structural volumes to the point where automated volume estimation may now have the accuracy of manual estimation.

There are two aims to the current study:

1. Validate the use of automated volumetric measurement in two populations (healthy controls and people diagnosed with AD or MCI), comparing manual versus automated measurements for three regions of interest: hippocampus, entorhinal cortex and perirhinal cortex.
2. Examine the relationship of clinical memory function to cortical thickness in three regions, hippocampus, entorhinal cortex and perirhinal cortex, measured through both manual and automated methods.

Progress to Date

We have used the Brain Foundation Gift to support the PhD research program of Ms Yi Leng Fung who is a Masters/PhD combined degree student in Clinical Neuropsychology in the Melbourne School of Psychological Sciences. Specifically, the Brain Foundation Gift has been used to pay for control participant imaging and research assistance time to augment our clinical archive as explained below. To date Ms Fung has examined and manually delineated mesial structures from 60 MRI scans in memory clinic sample and generated estimated hippocampal, and entorhinal perirhinal cortical volumes in this sample.

Secondly, preliminary visual inspection of FreeSurfer's (version 5.3) automated output of the entorhinal (Brodmann's area 28) and perirhinal (Brodmann's area 35) structures revealed significant overlap between these two structures, and the lateral and medial borders of the structures have significant variability, which questioned the reliability of the current automated estimation methods, although these methods are widely used in published studies.

Several queries regarding the structural overlap have been directed to the FreeSurfer's development team.

Preliminary findings

This progress report presents preliminary findings relating to the first aim:

1. Validate the use of automated volumetric measurement in two populations (healthy controls and people diagnosed with AD or MCI), comparing manual versus automated measurements for three regions of interest: hippocampus, entorhinal cortex and perirhinal cortex.

Analyses included 60 clinical scans of patients between the ages of 40 – 89, of which a total of 60 total hippocampal volumes, and a subset of 30 total entorhinal volumes and 30 total perirhinal volumes were obtained. All manual tracings were outlined using Analyze 12.0 (Brain Imaging Resource, Mayo Clinic, Rochester, MI, USA). Automated volumetric measurements were performed with FreeSurfer v5.3. Statistical analysis was carried out using SPSS v21.

Paired sample t-test showed that FreeSurfer's automated volumes were significantly larger than manual volumes on all three structures, namely total hippocampal volume ($t = 13.028$, $df = 59$, two-tailed $p < .001$), total entorhinal volume ($t = 4.393$, $df = 29$, two-tailed $p < .001$) and total perirhinal volume ($t = 23.658$, $df = 29$, two-tailed $p < .001$).

There was very strong correlation of FreeSurfer values with manual segmentation for total hippocampal volume ($r_s = .879$, $p < .001$), while correlation between entorhinal volumes was moderate ($r_s = .475$, $p = .008$) and there was no significant correlation between the automated and manual perirhinal volumes. Examples of the automated (Analyze) and manual (FreeSurfer) hippocampal tracings revealed similar anatomical landmarks for delineation (Figure 1). Ms Yi Leng Fung has made several conference presentations on methods and results to date. See below.

While the results for the hippocampal volume estimation show that FreeSurfer can be used to provide cost-effective estimation of this structure, estimates for the other structures require further refinement to achieve the aim of providing a volumetric imaging algorithm to aid clinical diagnosis.

Further investigation of the FreeSurfer algorithms has identified some of the sources of inconsistency in the estimation of perirhinal volumes, namely, individual variation in collateral sulcal conformity. Recently Ms Yi Leng Fung has devoted considerable effort to developing a method by which to classify four common types of collateral sulcus variation. These variations are currently not accommodated in the FreeSurfer methods.

During 2016, we have been fortunate to develop a research collaboration with the CSIRO Brain Image Analysis Team based at the University of Queensland. Having access to high-capacity computing, the CSIRO team is able to process images using FreeSurfer much faster than we can, and so are aiding in aspects of our overall data analysis. We are also working with the CSIRO group in the development and refinement of an entorhinal/perirhinal algorithm which we can re-validate against the Analyze methods in our existing data.

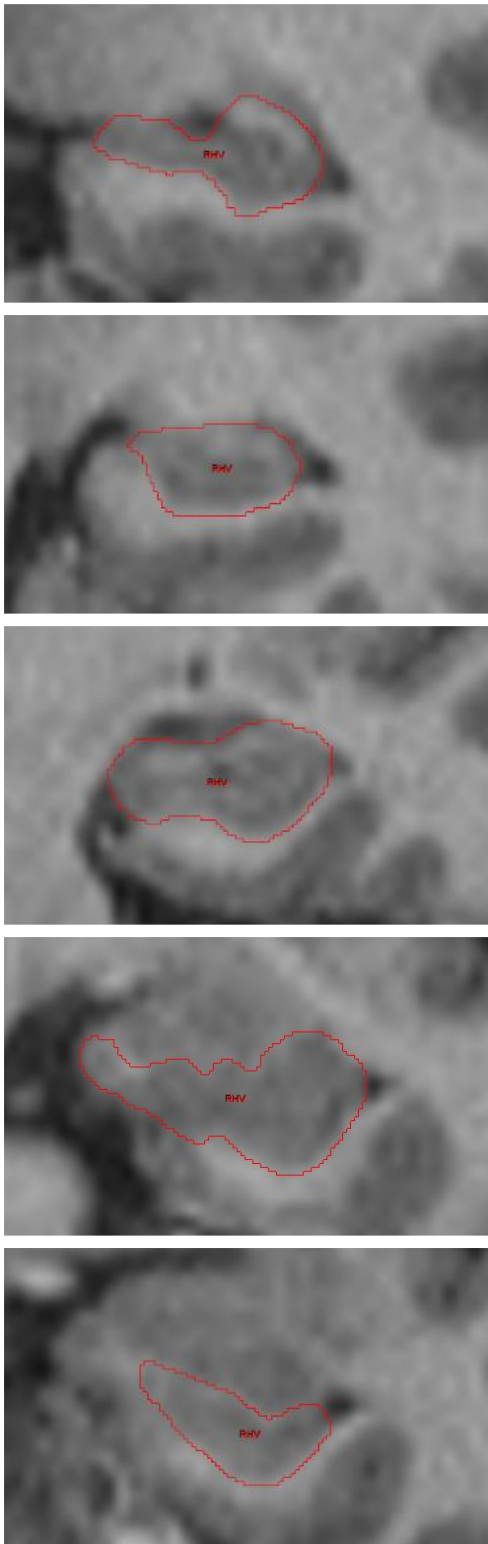
We have also extended our collaboration with colleagues working in the geriatric psychiatry service at St George's Hospital in Melbourne. This service has a long running and busy memory clinic and through this collaboration, which has received St Vincent's HREC approval, we anticipate augmenting our sample of patients with suspected dementia by 2-300 participants. This larger sample will give ample design power to investigate more questions in relation to dementia subtypes, and diagnostic algorithms.

Unanswered questions

Other questions that will be answered in this project will include:

1. Validation of the automated segmentation for the entorhinal and perirhinal cortex, particularly in the updated version of FreeSurfer (version 6 and above). As noted above, visual inspection and statistical findings of the automated segmentation of these two structures using FreeSurfer version 5.3 suggest limited reliability based on preliminary results.
2. Investigation of whether there will be any significant differences in reliability of volumetric findings of control versus clinical scans.
3. Understand the relationship of these mesial temporal structure volumes with clinical cognitive outcomes.

Manual segmentation



FreeSurfer automated segmentation

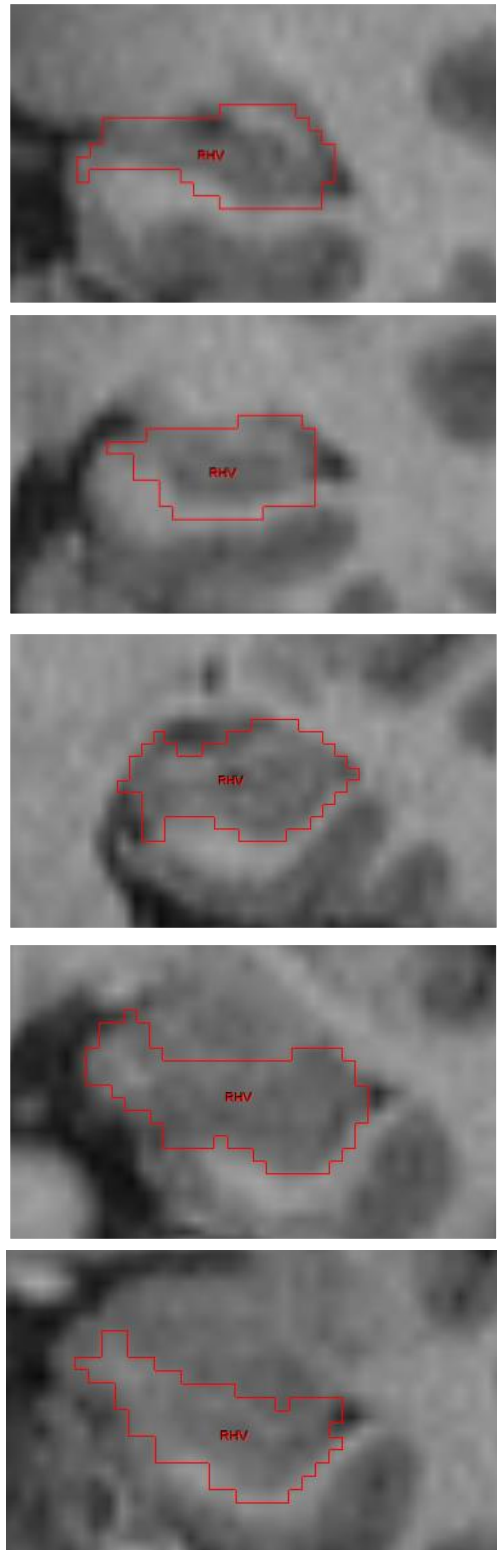


Fig 1.

Comparison of anatomical boundaries in Analyze manual and FreeSurfer automated segmentation in the right hippocampus.

What these research outcomes mean

The current preliminary results suggest that despite FreeSurfer's statistically inflated hippocampal volumes in comparison to manual measurements, this inflation appears to be a stable source of bias and there is high correlation between automated and manual hippocampal segmentation. FreeSurfer estimates also demonstrated robust performance on clinical scans across variable atrophy severity, which supports the potential utility of FreeSurfer in a clinical setting to assess hippocampal integrity. As detailed above, rhinal cortex measurement is undergoing refinement.

Although we had anticipated submitting an NHMRC project grant application in March 2017, to pursue this research on a larger scale, instead we anticipate submitting such application in March 2018, with a much stronger proposal.

Conference Presentations

Fung, Y. L., Ng, K. E., Vogrin, S., Meade, C., Collins, S., & Bowden, S. (2015, July). Validation of automated hippocampal volumetric measures in a clinical population. Poster session presented at the 5th INS/ASSBI Pacific Rim Conference, Sydney, NSW, Australia.

Fung, Y. L., Ng, K. E., Vogrin, S., Meade, C., Collins, S., & Bowden, S. (2015, November). Validating the clinical utility of automated hippocampal volumetry. Poster session presented at the 21st Annual Conference APS College of Clinical Neuropsychology, Shoal Bay, NSW, Australia. **Winner of the best student poster prize at the conference.**

Fung, Y. L., Ng, K. E., Vogrin, S., Meade, C., Collins, S., & Bowden, S. (2016, August). Validating automated hippocampal segmentation in a clinical population. Poster session presented at ACMD Research Week, St Vincent's Hospital, Fitzroy, VIC, Australia.